

Differential Diagnosis of NICO Lesions

Wesley E. Shankland, II, D.D.S., M.S., Ph.D.

TMJ & Facial Pain Center

Columbus, OH

Introduction

The diagnosis and treatment of orofacial pain are challenges to the clinician as well as frustrating to the one afflicted. At least two reasons account for these observations. Anatomically, the orofacial region is one of the most highly innervated areas of the human body, especially the oral cavity. Referred pain patterns, collateral innervation, and multiple innervations of structures all confuse a person's perception as to the location of the pain generator (i.e., a lesion or injured structure). This honest confusion complicates the doctor's diagnostic attempts.

In addition, the head and face are subject to chronic or recurring pain more than any other portion of the body.¹ A 1983 study² revealed that the average facial pain sufferer sought relief from at least six separate practitioners in their quest for an answer to their orofacial pain. Thus, dentists engaged in general practice, treating the numerous, common dental conditions which produce pain, have a difficult task.

In this brief treatise, the topic of diagnosing neuralgia inducing cavitation osteonecrosis (NICO) of the jaws will be addressed. However, before that subject is introduced, attention must be given to the differential diagnosis of a common and similar disorder, trigeminal neuralgia.

Trigeminal Neuralgia

Cranial neuralgias are real management problems and often the most frustrating disorders to evaluate and treat. Unfortunately, dental students, residents and medical students are taught that sharp, severe pain in and about the distribution of the trigeminal nerve is trigeminal neuralgia, or *tic douloureux*. Rarely is there a distinction between what are actually two separate disorders; namely typical and atypical trigeminal neuralgia.³

Typical Trigeminal Neuralgia. Typical trigeminal neuralgia (TTN), or what is usually

-
1. Merritt HH: Forward in: *Facial Pain and Mandibular Dysfunction*, Schwartz L, Chayes CM (eds). Philadelphia: WB Saunders Co, 1968:v.
 2. Shankland WE: Differential diagnosis of headache pain. *J Craniomand Pract* 1986;4:47-52.
 3. Shankland WE: Trigeminal neuralgia: typical or atypical? *J Craniomand Pract* 1993;11:108-112.

(and correctly) termed *tic douloureux*, may be subdivided into either idiopathic or symptomatic. The actual cause of idiopathic is not known, but the literature provides some interesting ideas. There have been reports that pulpal infection, pulpal inflammation, or pulpal removal (by endodontic therapy or tooth extraction) may be a major cause of idiopathic TTN.^{4,5,6} Further, the formation of osteocavital lesions, or NICO lesions, at former extraction sites or apical to endodontically treated teeth are now implicated as yet another cause of idiopathic trigeminal neuralgia.^{7,8,9}

As a side note, just think what we, as dentists, may be doing to contribute to the development of trigeminal neuralgia with all the unnecessary removal of third molars and worse yet, endodontic procedures we perform each year in an attempt to practice as *organized dentistry dictates and state dental boards demand*.

In contrast to idiopathic typical trigeminal neuralgia, the symptomatic type is produced by any neurological deficit, intracranial lesion, or impingement of the trigeminal nerve by aberrant vessels or connective tissues. Although such neurological diseases as aneurysms, multiple sclerosis and brain tumors (e.g., meningioma, epidermoid cyst, acoustic neuroma) produce TTN within the cranium, the most common cause is compression of the trigeminal rootlets as they exit the pons by the superior cerebellar artery. Dandy¹⁰ first reported this in 1934 and Jannetta¹¹ perfected the surgical procedure to correct the problem.

The clinical features of typical trigeminal neuralgia, whether idiopathic or symptomatic, are (Table 1):

-
4. Dodd J, Kelly JP: Trigeminal system. In, *Principals in Neuroscience*, 3rd ed. Kandell ER, Schwartz JH, Jessell TM (eds). New York: Elsevier, 1991:705-710.
 5. Sessle BJ: Recent developments in pain research: central mechanisms of orofacial pain and its control. *J Endodon* 1986;12:435-444.
 6. Dykes RW: Central consequences of peripheral nerve injuries. *Ann Plast Surg* 1984;13:412-422.
 7. Fromm GH: Trigeminal neuralgia and related disorders. *Neurol Clin* 1989;7:305-318.
 8. Ratner EJ, Person P, Kleinman DJ, Shklar G, Socransky SS: Jawbone cavities and trigeminal neuralgia and atypical facial neuralgias. *Oral Surg* 1979;48:3-20.
 9. Shaber EP, Krol AJ: Trigeminal neuralgia—new treatment concept. *Oral Surg* 1980;49:286-293.
 10. Dandy W: Concerning the cause of trigeminal neuralgia. *Am J Surg* 1934;24:447-455.
 11. Jannetta PJ: Arterial compression of the trigeminal nerve at the pons in patients with trigeminal neuralgia. *J Neurosurg* 1967;26:159-162.

1. Paroxysmal facial pain confined to the distribution of the trigeminal nerve
2. Sharp, burning, electrical pain produced by touch the face, chewing, shaving, apply make-up, talking, washing the face, brushing teeth, or even kissing
3. Pain that is usually unilateral with slightly greatly predilection for the right side
4. Onset of pain generally after age 50
5. The second division is affected most often, with the third division affected far more often than the first division
6. Normal neurological findings

The diagnosis of TTN is usually based on history, negative brain scans (MRI and CT scans) for tumors and aneurysms, and positive response to medication. If an aberrant vessel is seen on MRI evaluation overlying the trigeminal nerve, neurosurgery is usually indicated and pharmacological management will be ineffective for any length of time.

Atypical Trigeminal Neuralgia

In contrast to typical trigeminal neuralgia, atypical trigeminal neuralgia (ATN) is far more common and yet, most often misdiagnosed as *tic douloureux*. In over 22 years of practice, with the past 16 years limited to the diagnosis and treatment of facial pain disorders, I have only seen approximately 20 actual cases of TTN, but have diagnosed several hundred cases of the atypical type. Atypical trigeminal neuralgia is also known as idiopathic trigeminal neuralgia and pre-trigeminal neuralgia.

As with TTN, ATN has no known specific cause. However, in my clinical experience, crushing or compression of nerves (e.g., with surgical flap retraction), transection of nerves (either from trauma or surgical incision), blunt trauma to the face, or routine dental procedures (e.g., typical local anesthetic injection or an endodontic procedure) have been common causes.

Symptoms of ATN include (Table 1):

1. Constant pain with an aching quality that seems to arise from deep within the bone or soft tissue
2. Exacerbations of sharp, shooting, electrical type pains concurrently with the deeper, constant aching pain
3. Unilateral pain that follows the distribution of one division of the trigeminal nerve
4. The presence of trigger areas or zones which are frequently, but not consistently, intraoral
5. No specific age boundaries

The diagnosis of ATN should be based on history of the disorder, response to diagnostic anesthetic injections, and the results of imaging findings. The most important diagnostic procedure a doctor can perform to diagnose ATN is giving an anesthetic injection. If the pain complaints are totally relieved, then both doctor and patient can be assured (generally) the

neuralgia is of extracranial and not intracranial in origin. This is extremely important in determining the prognosis of any future treatment.

If an anesthetic injection stops the patient’s pain symptoms and radiographs reveal bony abnormalities, then one must highly suspect a NICO lesion or lesions.

Conservative treatment of ATN consists of the use of medications, localized injections of anti-inflammatory medications (I prefer Sarapin¹² as it has all the good qualities of cortisone without the side-effects) mixed with local anesthetic. These injections often need to be repeated every two to four weeks.

If conservative therapy fails, then the most effective surgical procedure for the treatment of ATN is percutaneous radiofrequency thermoneurolysis.

Table 1: Symptoms of Typical versus Atypical Trigeminal Neuralgia

Symptoms	Typical Trigeminal Neuralgia	Atypical Trigeminal Neuralgia
Pain	Sharp, Electrical, Shooting	Dull, Deep Aching
Duration	Seconds	Constant
Frequency	Paroxysmal	Constant
Location	V2 & V3 usually	All 3 Divisions
Triggers	Extra-Oral	Varies: Extra and Intra-Oral

Neuralgia Inducing Cavitation Osteonecrosis

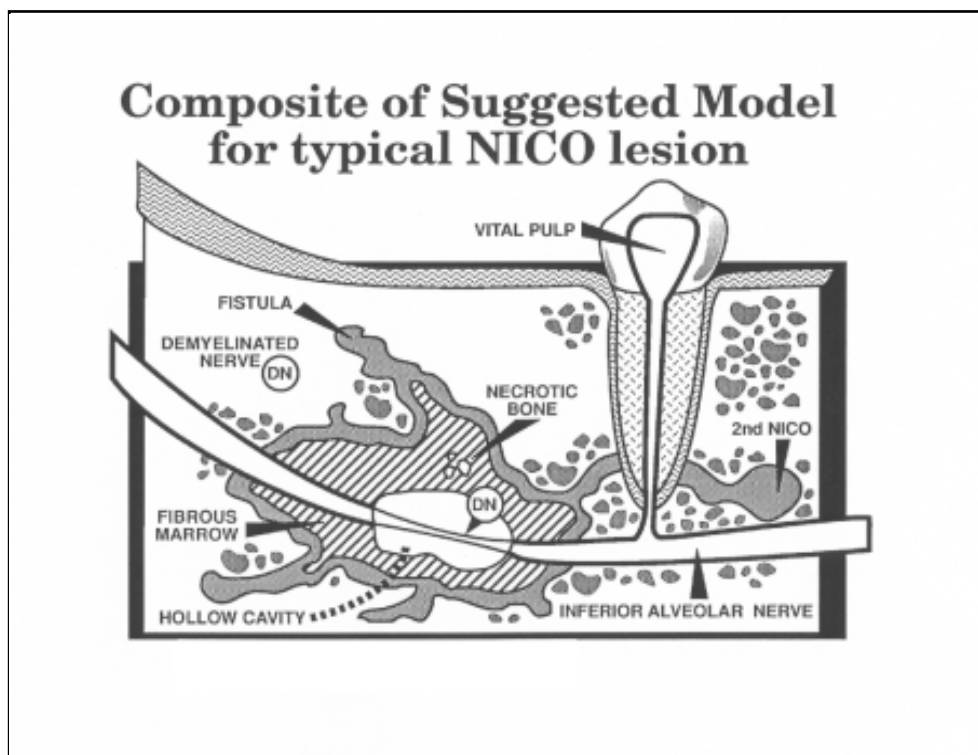
As stated at the beginning of this article, chronic orofacial pain is both common and frustrating to the patient and doctor. A 23.3% risk of developing chronic facial pain exists by age 50 and a 33.8% risk by age 70.¹³ Many researchers and clinicians alike contend that peripheral neural damage is a major etiological factor for the development of trigeminal-like pain. This

12. High Chemical Company, Levittown, PA.

13. Von Korff M, Dworkin SF, Le Resche L, Kruger A: An epidemiologic comparison of pain complaints. *Pain* 1988;32:173-183.

peripheral theory states that a low-grade, chronic, intraosseous infection near a branch of the trigeminal nerve may produce neuronal degeneration or demyelination producing inappropriate nociceptive signals to the central nervous system (Figure 1).¹⁴ This typically is explained by neuralgia inducing cavitation osteonecrosis (NICO) or cavitation lesions.

Figure 1: Diagrammatic representation of NICO lesions.¹⁵



14. Roberts AM, Person P: Etiology and treatment of idiopathic and atypical facial neuralgias. *Oral Surg* 1979;48:298-308.

15. This diagrammatic figure is copyrighted © by Wesley Shankland, DDS, PhD. All rights reserved. This figure may not be copied in any fashion (including electronic scanning) without permission of Wesley Shankland, DDS, PhD.

Simply defined, *osteonecrosis* is dead bone; *osteomyelitis* is inflammation of the bone marrow and adjacent bone. In 1915, G. V. Black¹⁶ first described these jawbone lesions as follows: “An osteomyelitis-like bone disease which seemed not to be a true infection, but rather a slow, progressive, unexplained death of cancellous bone and marrow, cell by cell.” These lesions were not new to dentistry, for dental surgeons in the United States accepted this theory in the 19th century.^{15,16} The theory of osteomyelitic and osteonecrotic jawbone lesions producing trigeminal neuralgia-like pains is supported by laboratory evidence that Gasserian ganglion degeneration occurs after damage to the pulp of teeth^{17,18} and by the high rate of relief of long-term trigeminal neuralgia pain after surgical treatment of the jawbone cavitations which failed to respond to traditional medical procedures.

The thought that osteocavitations of the jawbones produce trigeminal pain has not only recently gained acceptance in the United States¹⁹, but also in Germany,²⁰ Russia,²¹ China,^{22,23} and Great Britain.²⁴

-
16. Black GV. A Work on Special Dental Pathology. Chicago: Medico-Dental Publ Co, 1915.
 515. Grandin DS: Neuralgia facialis. *Am J Dent Sci* 1841;1:251-253.
 16. Tomes J: A course of lectures on dental physiology and surgery, lectures X-XII. *Am J Dent Sci* 1848;8:209-246.
 17. Black RG: A laboratory model for trigeminal neuralgia. *Adv Neurol* 1974;4:651-658.
 18. Westrum LE, Canfield RC: Electron microscopy of degenerating axons and terminals in spinal trigeminal nucleus after tooth pulp expirations. *Am J Anat* 1976;100:137-140.
 19. Shankland WE: Osteocavitation lesions (Ratner bone cavities): frequently misdiagnosed as trigeminal neuralgia—a case report. *J Craniomand Pract* 1993;11:232-235.
 20. Machtens E: Atypical pain (neuralgiaform pain). *Zahnarzt Welt Rundsch* 1977;86:945-951.
 21. Grecko VE, Puzin MN: Odontogenic trigeminal neuralgia. *Zh Nevropatol Psikhiatr* 1984;84:1655-1658.
 22. Jiao X, Meng Q: The influence of pathologic bone cavity of jaw bone on the etiopathology of trigeminal neuralgia. *Act Acad Med Sichuan* 1981;12:243-247.
 23. Wang M, Jiao X, Meng Q, Zhang S: A study of the relation between the various trigger zones of idiopathic trigeminal neuralgia and jaw bone cavities. *Acta Acad Med Sichuan* 1982;13:233-238.
 24. Wannfors K, Gazelius B: Blood flow in jaw bones affected by chronic osteomyelitis. *Br J Oral Maxillofac Surg* 1991;29(3):147-153.

The symptoms of NICO are:

1. A history of undiagnosed facial and cervical pain
2. A history of tooth extraction, which may have occurred decades earlier
3. The presence of trigger areas
4. Normal radiographic findings^{17*}

Patients suffering from cavitational lesions will generally have a history of tooth extraction perhaps many years before the onset of pain complaints. Also, a common history includes the placement of a large restoration or crown, followed by the development of sensitivity or pain, neither of which can be resolved. The patient then demands or the doctor recommends endodontic therapy, but unfortunately, the pain continues.

Etiological factors known to influence the development of NICO lesions include:

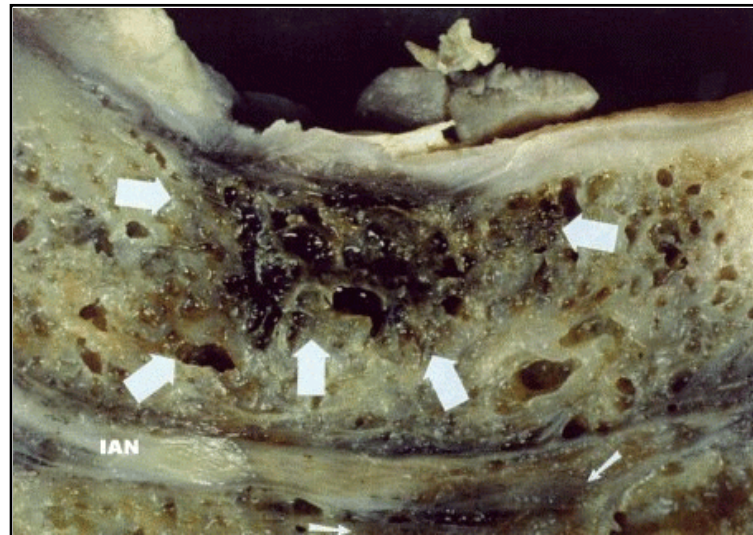1. Trauma, which may be blunt trauma to the jaws or trauma from dental procedures such as routine oral and periodontal surgical procedures
2. History of a large dental restoration followed by the development of pulpitis and ultimately, chronic periapical periodontitis
3. Heavy and/or chronic use of systemic cortisone
4. Use of birth control pills
5. Estrogen replacement therapy
6. Radiation therapy
7. Variable atmospheric pressures in occupation
8. Alcoholism
9. Sickle cell anemia
10. Heavy cigarette smoking
11. Pregnancy
12. Thrombophilia
13. Hypofibrinolysis

The underlying microscopic problem is vascular insufficiency, with intramedullary

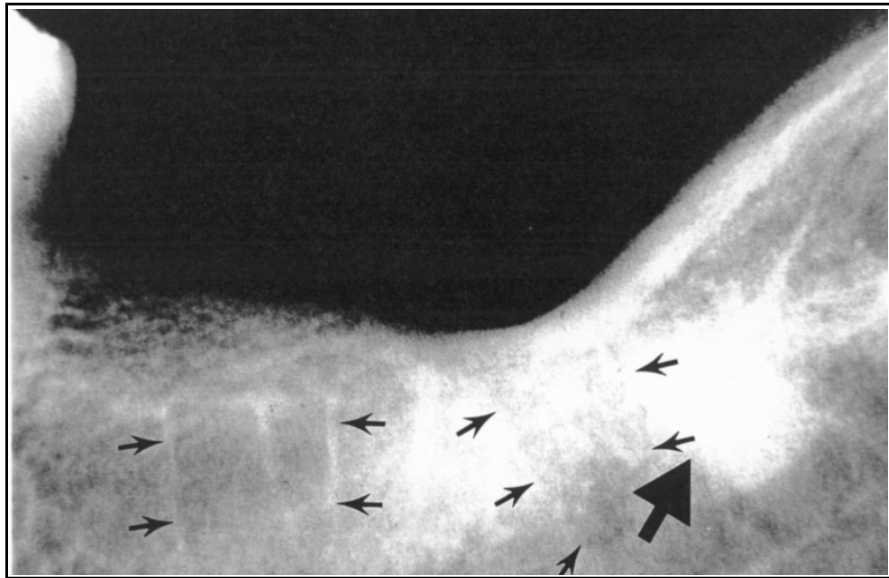*These findings are considered *normal* as generally taught in dental schools and residency programs. However, as one becomes experienced in diagnosing NICO lesions, the radiographic appearance can be described as anything but normal (see Figure 3).

hypertension and multiple intraosseous infarctions occurring over time.^{25,26} In other words, an occlusion of one or several of the tiny intramedullary vessels by thrombi within the maxilla or mandible occurs, producing ischemic changes distal to the vessel blockage, ultimately resulting in the development of osteomyelitis and/or osteonecrosis. These thrombi may be caused by rigid erythrocytes blocking the vessels of the bone marrow (Figure 2). Glueck achieved a substantial breakthrough when he reported that a majority (65% to 87%) of osteonecrosis patients had major hereditary or acquired clotting disorders that had not previously been diagnosed or even suspected.^{27,28}

Figure 2: Gross appearance of a large NICO lesion.



-
25. Adams WR, Spolnik KJ, Bouquot JE: Maxillofacial osteonecrosis in a patient with multiple “idiopathic” facial pains. *J Oral Pathol Med* 1999;28:423-432.
 26. Bouquot JE, LaMarche MG: Ischemic osteonecrosis under fixed partial denture pontics: radiographic and microscopic features in 38 patients with chronic pain. *J Prosthet Dent* 1999;81:148-158.
 27. Glueck CJ, Freiberg R, Glueck HI, Henderson C, Welch M, Tracy T et al: Hypofibrinolysis: a common, major cause of osteonecrosis. *Am J Hematol* 1994;45:156-168.
 28. Glueck CJ, McMahon RE, Bouquot JE, Stroop D, et al: Thromophilia, hypofibrinolysis and osteonecrosis of the jaws. *Oral Surg Oral Med Oral Pathol* 1996;81:557-566.



Radiographic features are quite interesting. Initially, one unreliable diagnostic tool was the radiograph, because features which were taught as being normal (e.g., ghost images, laminar rain, retained outline of extracted roots of teeth), were dismissed as being insignificant. Many cases cannot be identified even by experienced diagnosticians simply because osteonecrosis is primarily a disease of cancellous bone and that 30% to 50% of cancellous bone must be destroyed before radiographic changes become evident.²⁹

However, it is now recognized that approximately 75% of these patients demonstrate radiographically visible vertical remnants of lamina dura. In addition, many patients display a relatively complete, albeit faint sometimes faint, outline of the former tooth roots. Other radiographic signs are ragged, zigzagged vertical remnants of the lamina dura and apparent remodeling or healing of the apical portion of the socket (Figure 3).

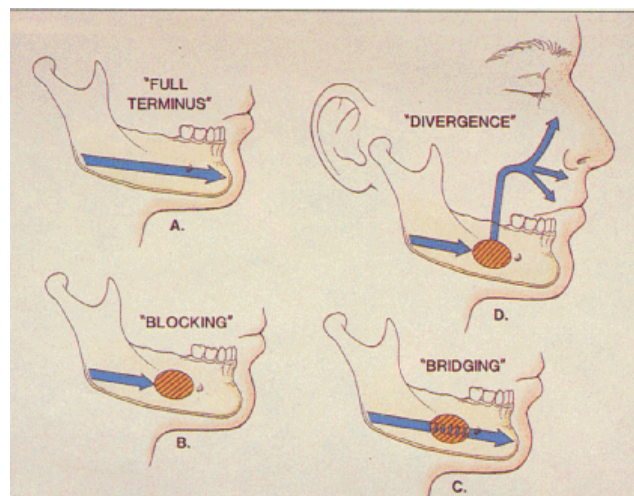
29. Bender JB, Seltzer S: Roentgenographic and direct observation of experimental lesions in bone. *J Am Dent Assoc* 1961;62:152-160, 708-716.

Figure 3: Radiographic appearance of NICO lesion in mandible. Note outlines of former roots (left) and outlines of roots and condensing osteitis (right).

Panoramic radiographs are very useful in evaluating suspected patients. Periapical radiographs are more diagnostic and reliable, however. At time, bone scans using the radioisotope technetium-99 are also helpful, but difficult to interpret in the orofacial regions.

In addition to radiographic evaluation, probably the best diagnostic tool is the use of anesthetic blocking. McMahon et al³⁰ embellished Ratner's⁸ work concerning anesthetic confirmation of NICO lesions. Briefly, because products of inflammation can *sensitize* branches of the trigeminal nerve, the clinician must search for patches of unanesthetized gingivae that may be signaling underlying pulpal or intrabony pathoses (Figure 4).

Figure 4: Diagram of interruptions of normal anesthetic blocking by NICO lesions.



The most common location of NICO lesions is the mandibular third molar region, with the first molar region being the next common location (Table 2). The least common areas are the mandibular central and lateral incisor areas.

30. McMahon RE, Adams W, Spolnik KJ: Diagnostic anesthesia for referred trigeminal pain: part 1. *Compend Contin Educ Dent* 1992;11:870-881.

Table 2: Location of NICO lesions.

<i>Table 4: Location of 2,301 NICO lesions as reported on biopsy request forms from 1,333 patients with facial pain.³⁷ Numbers represent the proportion (%) of all cases found at a specific site (first surgery only).</i>			
<i>Alveolar location</i>	<i>Maxilla</i>	<i>Mandible</i>	<i>Total</i>
<i>Central incisor area</i>	<i>2.5 %</i>	<i>0.2 %</i>	<i>2.7 %</i>
<i>Lateral incisor area</i>	<i>3.6</i>	<i>0.2</i>	<i>3.8</i>
<i>Cuspid area</i>	<i>5.0</i>	<i>2.0</i>	<i>7.0</i>
<i>First bicuspid area</i>	<i>5.2</i>	<i>1.1</i>	<i>6.3</i>
<i>Second bicuspid area</i>	<i>4.8</i>	<i>3.4</i>	<i>8.2</i>
<i>First molar area</i>	<i>6.8</i>	<i>12.6</i>	<i>19.4</i>
<i>Second molar area</i>	<i>2.6</i>	<i>5.1</i>	<i>7.7</i>
<i>Third molar area *</i>	<i>20.0</i>	<i>24.9</i>	<i>44.9</i>
<i>Total:</i>	<i>51.5 %</i>	<i>48.5 %</i>	<i>100.0 %</i>

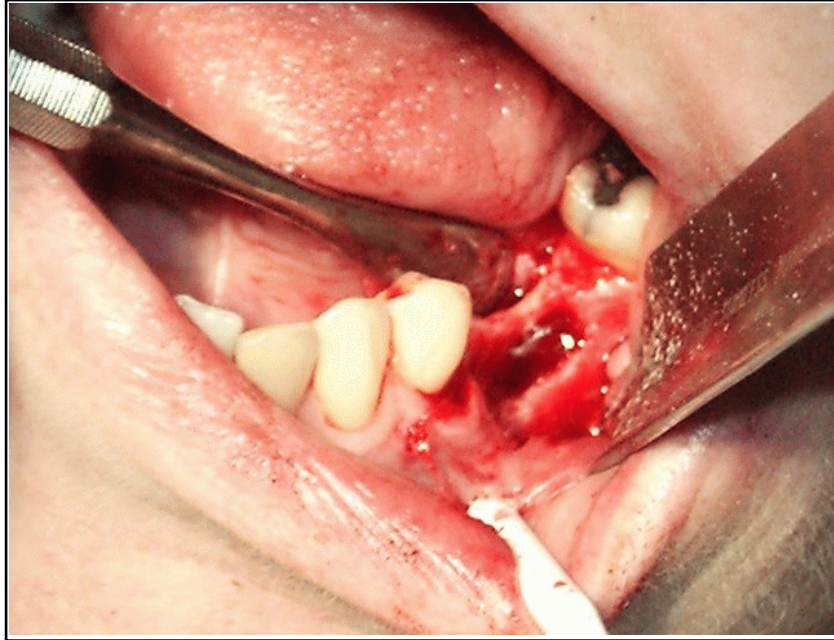
** includes tuberosity and retromolar areas*

Treatment of NICO lesions *always requires surgical removal of the affected bone*, whether the actual diagnosis is osteomyelitis or osteonecrosis. I realize this is a controversial statement to members of the International Academy of Oral Medicine and Toxicology since many of our members prefer to use homeopathic and natural remedies. Unfortunately, if an infected bony area does not have a blood supply, no remedy, be it homeopathic or allopathic, can be distributed within the region. Also, localized injections of homeopathic remedies using intrabony injections (e.g., the Stabident¹⁸ system) have not proven to be successful. Thus, only surgery gives the patient a chance for any degree of recovery.

Generally, after reflection of a full thickness flap, the cortical plate of the bone is removed and the offending bony tissue is removed with curettage, taking special care to avoid the inferior alveolar nerve and vascular supply in the mandible and the maxillary sinus, if possible, in the maxillary. Oftentimes, the contents of the inferior alveolar canal must be moved while the pathologic bony tissue is removed and at times, the nerve and blood vessels must be relocated within the mandible (Figure 5).

¹⁸Stabident intraosseous infiltration system, Fairfax Dental, Miami, Florida.

Figure 5: Reflection of full thickness flap over a previously "healed" extraction site in left mandibular region. Lesion as it appeared upon flap reflection, an empty cavity in the bone surrounded by dead marrow.



In the maxilla, it is common that the maxillary sinus is affected and therefore, must be entered and the floor and/or walls reconstructed.

Also, any teeth located within these pathologic regions must be removed and generally, they are shown to be non-vital upon post-operative examination.

Lastly, recently we have discovered that many of those afflicted with NICO lesions are also suffering with yeast infections, both localized in the questionable bony regions and systemically. Therefore, our surgical success has been improved by placing patients on Cefzil 250 mg twice a day a week prior to surgery and at least 30 days after surgery. Also, when symptoms seem to continue post-operatively, prescribing Diflucan 400 mg the first day and 200 mg once daily for at least 4 weeks.

Summary

As dental practitioners, we ultimately encounter most orofacial pain complaints. Understanding trigeminal neuralgia and NICO lesions is of the utmost importance, lest patients continue to suffer and receive inappropriate and unnecessary treatments.

Recommended Reading

1. Bouquot JE, McMahon RE. *Maxillofacial Osteonecrosis Part I: Review of NICO*. The Maxillofacial Center, Morgantown, WV, 1998.
2. Bouquot JE, McMahon RE. *Ischemic Osteonecrosis of the Jaws Part I: A Review of NICO*. The Maxillofacial Center, Morgantown, WV, 1996.
3. Bouquot JE, McMahon RE. *Ischemic Osteonecrosis of the Jaws Part II: Histopathological Review of NICO*. The Maxillofacial Center, Morgantown, WV, 1997.
4. Shankland WE: Craniofacial pain syndromes that mimic temporomandibular joint disorders. *Ann Acad Med Singapore* 1995;24:83-112.

Internet Sites With Good Information

1. <http://www.drshankland.com/nico.html>. Brief review of NICO lesions.
2. <http://www.maxillofacialcenter.com/>. Dr. Jerry Bouquot's web site with a lot of excellent information about NICO and oral pathology.
3. <http://www.quackwatch.com/index.html> These self-appointed health censors are legends in their own minds. You'll be shocked when you see what these *experts* consider as quackery. We all need to study this site so we'll know what our opposition is printing. By the way, both Dr. Bouquot's web site and my web site are listed by these people as sites of quackery.
4. <http://www.facepain.com/>. Great information about NICO and all types of facial pain.